

Supplemental Table 1 Percentage of medication used at baseline for included trials

| | Digoxin | Aldosterone antagonist | Beta blocker | ACEI or ARB |
|-------------------------------|---------|------------------------|--------------|-------------|
| MacDonald et al. ¹ | 51 | 32 | 88 | 95 |
| ARC-HF ² | 54 | 37 | 92 | 98 |
| CAMTAF ³ | NA | NA | 100 | 100 |
| AATAC ⁴ | NA | 48 | 78 | 90 |
| CAMERA-MRI ⁵ | NA | 41 | 97 | 94 |
| CASTLE-AF ⁶ | 25 | NA | 94 | 93 |

NA: not available

Supplemental Table 2 The detailed assessment process of cohort studies/randomized clinical trials included into present meta-analyses based on the nine-star Newcastle-Ottawa Scale

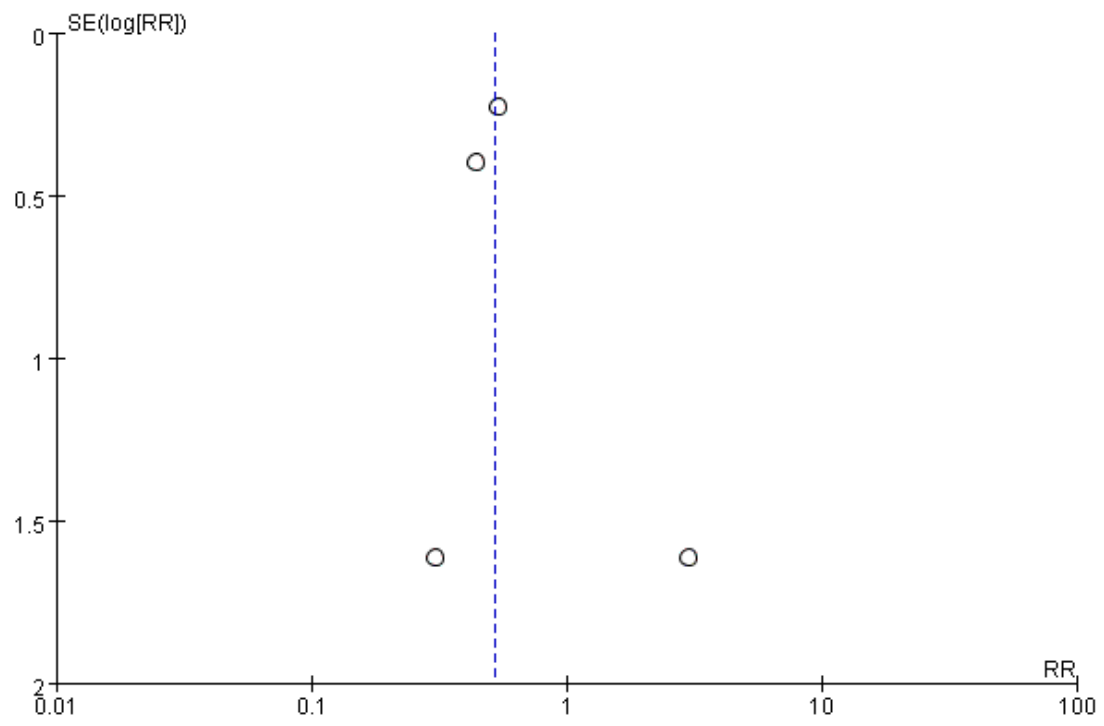
| | Selection 1) | Selection 2) | Selection 3) | Selection 4) | Comparability 1) | Outcome 1) | Outcome 2) | Outcome 3) | Score |
|-------------------------------|--------------|--------------|--------------|--------------|------------------|------------|------------|------------|-------|
| MacDonald et al. ¹ | a) | a) | b) | a) | a) b) | a) | b) | a) | 8 |
| ARC-HF ² | a) | a) | b) | a) | a) b) | a) | a) | a) | 9 |
| CAMTAF ³ | a) | a) | b) | a) | a) b) | a) | b) | a) | 8 |
| AATAC ⁴ | a) | a) | b) | a) | a) b) | a) | a) | a) | 9 |
| CAMERA-MRI ⁵ | a) | a) | b) | a) | a) b) | a) | b) | a) | 8 |
| CASTLE-AF ⁶ | a) | a) | b) | a) | a) b) | a) | a) | a) | 9 |

Supplemental Table 3 Complications of in a catheter ablation group

| | Major complication | Minor complication |
|-------------------------------|---|--|
| MacDonald et al. ¹ | 1 stroke 2 cardiac tamponade 3 worsening heart failure | NA |
| ARC-HF ² | 1 tamponade during ablation, requiring emergency pericardiocentesis and a sternotomy to repair a perforation at the atrioventricular groove | 1 groin hematoma, 1 chest infection 2 weeks post-ablation, and 1 patient with post-procedural pulmonary edema, which resolved within 24 h. |
| CAMTAF ³ | 1 stroke 1 tamponade | NA |
| AATAC ⁴ | 1 pericardial effusion that was conservatively managed with fresh-frozen plasma and protamine | 2 groin hematoma |
| CAMERA-MRI ⁵ | 1 groin site bleeding requiring blood transfusion 1 post-procedural pneumonia. | NA |
| CASTLE-AF ⁶ | 3 pericardial effusion, and 1 of these patients required pericardiocentesis. 3 severe bleeding that required blood transfusion (with 2 bleeding episodes from femoral puncture sites and 1 pseudoaneurysm, which was corrected surgically) | 1 asymptomatic pulmonary-vein stenosis |

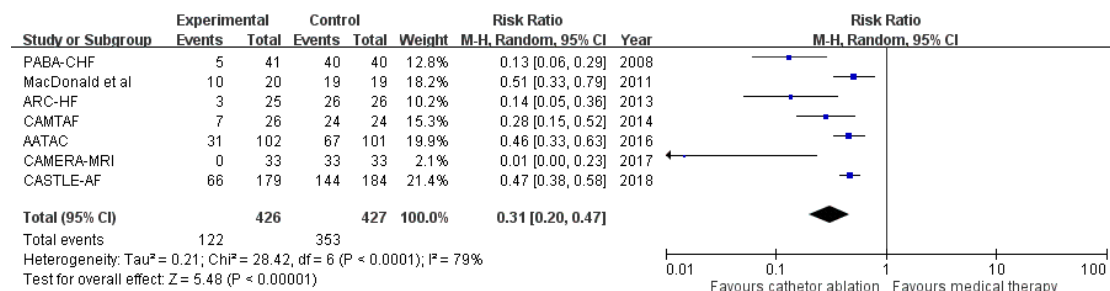
NA: not available

Supplemental Figure 1 Funnel plots of included trials

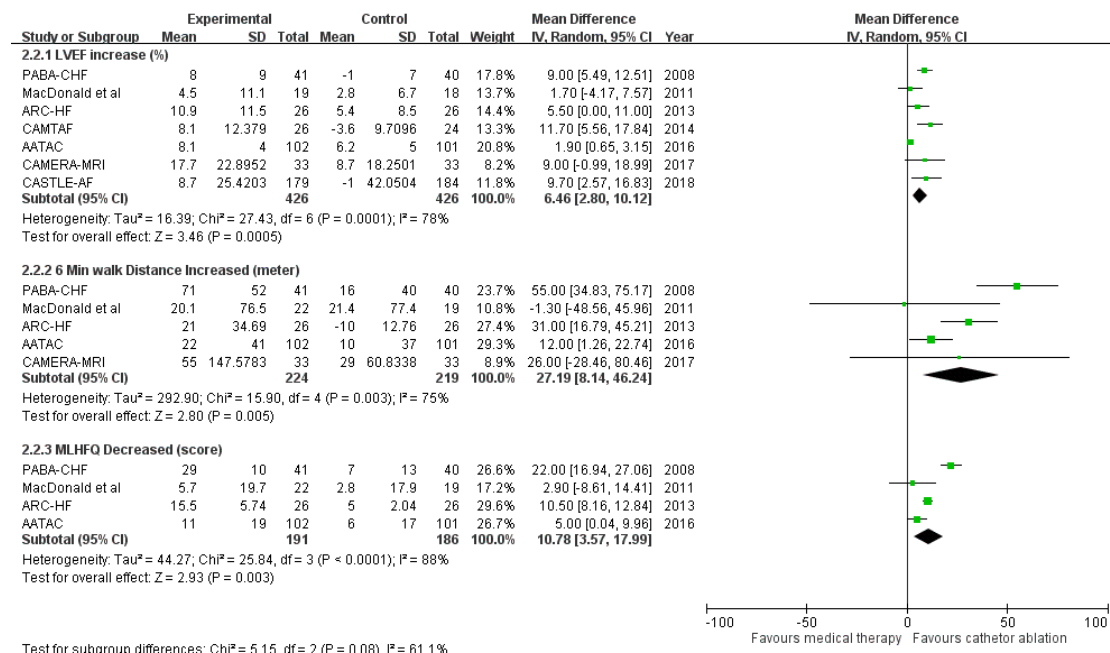


Supplemental Figure 2 Sensitivity Analysis with PABA-CHF⁷ Added to the Other Trials (A) Risk ratio with 95% confidence interval of heart failure hospitalization and remained in atrial fibrillation (catheter ablation for atrial fibrillation vs medical therapy); (B) Mean difference with 95% confidence interval in left ventricular ejection fraction (LVEF), 6-minute walk distance, and Minnesota Living with Heart Failure Questionnaire (MLHFQ)

(A)



(B)



REFERENCE

1. MacDonald MR, Connelly DT, Hawkins NM, Steedman T, Payne J, Shaw M, Denvir M, Bhagra S, Small S, Martin W, McMurray JJ and Petrie MC. Radiofrequency ablation for persistent atrial fibrillation in patients with advanced heart failure and severe left ventricular systolic dysfunction: a randomised controlled trial. *Heart*. 2011;97:740-7.
2. Jones DG, Haldar SK, Hussain W, Sharma R, Francis DP, Rahman-Haley SL, McDonagh TA, Underwood SR, Markides V and Wong T. A randomized trial to assess catheter ablation versus rate control in the management of persistent atrial fibrillation in heart failure. *Journal of the American College of Cardiology*. 2013;61:1894-903.
3. Hunter RJ, Berriman TJ, Diab I, Kamdar R, Richmond L, Baker V, Goromonzi F, Sawhney V, Duncan E, Page SP, Ullah W, Unsworth B, Mayet J, Dhinoja M, Earley MJ, Sporton S and Schilling RJ. A randomized controlled trial of catheter ablation versus medical treatment of atrial fibrillation in heart failure (the CAMTAF trial). *Circulation Arrhythmia and electrophysiology*. 2014;7:31-8.
4. Di Biase L, Mohanty P, Mohanty S, Santangeli P, Trivedi C, Lakkireddy D, Reddy M, Jais P, Themistoclakis S, Dello Russo A, Casella M, Pelargonio G, Narducci ML, Schweikert R, Neuzil P, Sanchez J, Horton R, Beheiry S, Hongo R, Hao S, Rossillo A, Forleo G, Tondo C, Burkhardt JD, Haissaguerre M and Natale A. Ablation Versus Amiodarone for Treatment of Persistent Atrial Fibrillation in Patients With Congestive Heart Failure and an Implanted Device: Results From the AATAC Multicenter Randomized Trial. *Circulation*. 2016;133:1637-44.
5. Prabhu S, Taylor AJ, Costello BT, Kaye DM, McLellan AJA, Voskoboinik A, Sugumar H, Lockwood SM, Stokes MB, Pathik B, Nalliah CJ, Wong GR, Azzopardi SM, Gutman SJ, Lee G, Layland J, Mariani JA, Ling LH, Kalman JM and Kistler PM. Catheter Ablation Versus Medical Rate Control in Atrial Fibrillation and Systolic Dysfunction: The CAMERA-MRI Study. *Journal of the American College of Cardiology*. 2017;70:1949-1961.
6. Marrouche NF, Brachmann J, Andresen D, Siebels J, Boersma L, Jordaens L, Merkely B, Pokushalov E, Sanders P, Proff J, Schunkert H, Christ H, Vogt J, Bansch D and Investigators C-A. Catheter Ablation for Atrial Fibrillation with Heart Failure. *The New England journal of medicine*. 2018;378:417-427.
7. Khan MN, Jais P, Cummings J, Di Biase L, Sanders P, Martin DO, Kautzner J, Hao S, Themistoclakis S, Fanelli R, Potenza D, Massaro R, Wazni O, Schweikert R, Saliba W, Wang P, Al-Ahmad A, Beheiry S, Santarelli P, Starling RC, Dello Russo A, Pelargonio G, Brachmann J, Schibgilla V, Bonso A, Casella M, Raviele

A, Haissaguerre M, Natale A and Investigators P-C. Pulmonary-vein isolation for atrial fibrillation in patients with heart failure. *The New England journal of medicine*. 2008;359:1778-85.